



Bochdalek hernia in adults – A case report

Bochdalek-ova hernija kod odraslih

Anita Ivošević*[†], Ivana Meta Jevtović[†], Vojislav Čupurdija*[†],
Ivan Čekerevac*[†], Aleksandar Radunović[‡], Milan Jovanović[§], Maja Vulović*,
Marko Spasić*^{||}, Marina Petrović*[†]

University of Kragujevac, *Faculty of Medical Sciences, Kragujevac, Serbia; Clinical Center Kragujevac, [†]Clinic of Pulmonology, ^{||}Clinic for General and Thoracic Surgery, Kragujevac, Serbia; Military Medical Academy, [‡]Clinic for Orthopedic Surgery and Traumatology, [§]Clinic of General Surgery, Belgrade, Serbia

Abstract

Introduction. Asymptomatic Bochdalek hernia in adults is a rarity. The aim of this paper is to present a rare case of Bochdalek hernia among adults and to point out to significance of clinical suspicion and important role of imaging techniques in reaching the exact diagnosis of this abnormality. **Case report.** A patient, aged 68 years, came to the Clinic of Pulmonology complaining of constant dyspnea, coughing and fatigue. Computed tomography (CT) findings were dominated by the large rear right diaphragmatic hernia with the hernial sac that reached the carina trachea and urged the principal bronchi. The stomach, duodenum and proximal part of jejunal winds, as well as a greater amount of omental and mesenteric adipose tissue were localized in hernial sac. Radiography of gastroduodenum showed: entry of the esophagus into the cardia was in the level of the right main bronchus. Stomach was mainly located in the chest (cardia, upper corpus half - to the level of the right main bronchus). Operation was indicated. First, we made right thoracotomy and the hernia sac was separated from the right lung and then we performed median laparotomy and the contents of the hernia sac were returned to the abdominal cavity; diaphragm defect was reconstructed with prolen mesh. **Conclusion.** We presented a rare case of right sided Bochdalek hernia which was discovered at late age and surgically treated with success.

Key words:

hernias, diaphragmatic, congenital; diagnosis; thoracic surgical procedures; digestive system surgical procedures; adults; treatment outcome.

Apstrakt

Uvod. Asimptomatska Bochdalek-ova hernija kod odraslih je raritet. Cilj rada je da se prikaže redak slučaj Bochdalekove hernije kod odraslih i da se naglasi značaj kliničke sumnje i značajna uloga imidžing tehnika u postavljanju tačne dijagnoze ove abnormalnosti. **Prikaz bolesnika.** Bolesnica, starosti 68 godina, se javila u Kliniku za pulmologiju zbog gušenja, kašlja i malaksalosti. U nalazu kompjuterizovane tomografije (CT) dominirala je velika zadnja desna dijafragmalna hernija čija kilna vreća je dopirala do nivoa karine i razmicala principalne bronhe. U kilnoj vreći se nalazio želudac, duodenum i deo proksimalnih jejunalnih vijuga, kao i veća količina omentalnog i mezenterijalnog masnog tkiva. Radiografijom gastroduodenuma ustanovljen je ulazak jednjaka u kardiju u nivou desnog principalnog bronha. Želudac se većim delom nalazio u grudnom košu (kardija, gornja polovina korpusa do nivoa desnog principalnog bronha). Indikovana je operacija. Urađena je prvo desna torakotomija i kilna kesha je odvojena od desnog plućnog krila, a zatim je urađena medijalna laparotomija i sadržaj kilne kesha je vraćen u trbušnu duplju. Defekt na dijafragmi je zbrinut prolenskom mrežicom. **Zaključak.** Predstavljen je redak slučaj desnostrane Bochdalek-ove hernije, otkriven u kasnijoj životnoj dobi i hiruški tretiran sa uspehom.

Ključne reči:

hernije, dijafragmalne, kongenitalne; dijagnoza; hirurgija, torakalna, procedure; hirurgija digestivnog sistema, procedure; odrasle osobe; lečenje, ishod.

Introduction

Congenital diaphragmatic hernia is frequently mentioned in medical literature since its first description dating back in the early 18th century ¹. It includes a number of birth

defects, the main characteristics of which are abnormalities in the development of the diaphragm ². It occurs due to the impossibility of closing of pleuroperitoneal fold between 4th and 10th week of gestation. It is the most common intrathoracic, extracardiac anomaly associated with high risk of

morbidity and mortality³. Congenital diaphragmatic hernia makes 8% of all major congenital anomalies. It generally occurs in the first hours after birth, whereas traumatic hernia can occur at any age. Subsequent clinical presentation of congenital diaphragmatic hernia is very rare². In adults, there are various causes such as: penetrating or blunt injury, physical effort, coughing episodes, sneezing, pregnancy and even eating too much food⁴. In 85% of cases congenital diaphragmatic hernia is localized on the left. The anatomical position of the liver and the barriers it creates are the reasons why congenital diaphragmatic hernia is localized on the right side in only 15% of cases². The contents of the hernial sac differ depending on which side the hernia is localized⁵. Bilateral hernias rarely occur and usually have fatal consequences. The most common form of congenital diaphragmatic hernia is a posterolateral or Bochdalek hernia. In most cases, Bochdalek hernia occurs in the neonatal period with poor prognosis¹. Asymptomatic Bochdalek hernia in adults is a rarity. Common clinical manifestations are problems with breathing or pneumonia. Symptoms of the gastrointestinal tract may be also present. Although rare, Bochdalek hernia may need to be considered in the differential diagnosis for patients in the old age who have foregut symptoms. A careful and unbiased interpretation of radiologic tests is essential to recognize the disease and perform the correct operation⁶. Imaging plays an important role in diagnosing and assessing the contents of the hernia and at the same time evaluating the presence of any associated abnormality⁷. The final diagnosis is set by computed tomography (CT)².

The aim of this report is to present a rare case of 68-years old patient with presentation of right-sided Bochdalek hernia, which is a rarity in clinical practice, as well as to point out to significance of clinical suspicion and important role of imaging techniques in reaching the exact diagnosis of this abnormality.

Case report

We presented a patient aged 68 years who came to the Clinic of Pulmonology at the Clinical Centre Kragujevac complaining because of constant dyspnea, coughing and fatigue. These symptoms lasted for several years, with intermittent periods without symptoms. Dry irritating cough and intensified malaise appeared ten days before admission. After completion of chest X-ray and having observed infiltrative paracardial lesion on the right side, the patient was hospitalized for further diagnostic and therapeutic procedures.

During the interview, the patient stated that during first years of her life she had often respiratory difficulties such as dyspnea and cough, mostly during night, with frequent respiratory tract infections due to which she had to seek medical help. She had no medical documentation on diagnosis or treatment. Since puberty, these difficulties were significantly less frequent and milder in intensity. They intensified again during last 5 years. She was treated for hypertension over last 10 years and over last 3 years for diabetes. There was no information on significant injuries neither on previous chest X-ray findings.

Auscultatory findings of the lungs were: diffusely impaired breathing sound, with occasional wheezing. Auscultation of the heart showed: rhythmical action, clear tones, systolic murmur at the top of the heart and over aorta. There were no other significant physical findings.

Radiography of the heart and lungs revealed: intense homogeneous soft-tissue infiltrative opacity over basal area of the right lung which closed right costophrenic sinus while left costophrenic sinus was free and the size of cardiac shadow was within the normal range (Figure 1). Bronchoscopic findings showed stenosis of bronchus for right lower lobe due to extramural compression. The rest of the findings were normal. Ultrasound findings of the abdomen were: liver, pancreas and spleen had normal echo structure. Gall bladder wall was thickened with two calculi of larger diameter - up to 2.8 cm. CT of the chest showed absence of pathological changes in the lungs, trachea and bronchi. There was no pleural effusion. CT findings were dominated by the large rear right diaphragmatic hernia with hernial sac that reached the carina trachea and urged the principal bronchi. The stomach, duodenum and proximal part of jejunal winds, as well as greater amount of omental and mesenteric adipose tissue was localized in hernial sac. Conclusion was: Hernia diaphragmalis Bochdalek l. dex (Figure 2). Radiography of gastroduodenum showed that: entry of the esophagus into the cardia was at the level of the right main bronchus. Stomach was mainly located in the chest (cardia, upper half of the corpus - to the level of right main bronchus). Stomach preserved form with no apparent defect in the filling of blood vessels and no elements of acute ulcer. Stomach was predominantly located in the retrocardiac space. Duodenal bulb, with no visible signs of acute ulcer disease, was located above the hemidiaphragmal contour in the chest cavity. The findings resembled Bochdalek hiatus hernia the most (Figure 3). The patient was treated surgically. Considering preoperative diagnosis of congenital hiatus hernia, discovered at the age of 68, massive adhesions between the hernial sac and thoracic organs were expected.

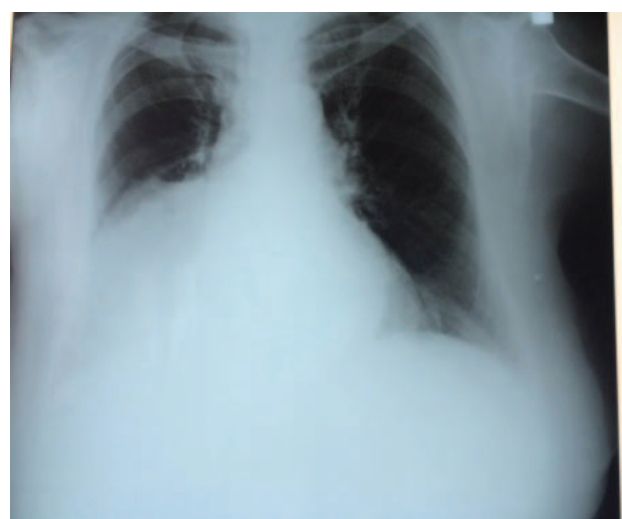

Fig. 1 – A posteroanterior chest radiograph shows an abnormal soft tissue opacity obscuring the right cardiac margin.

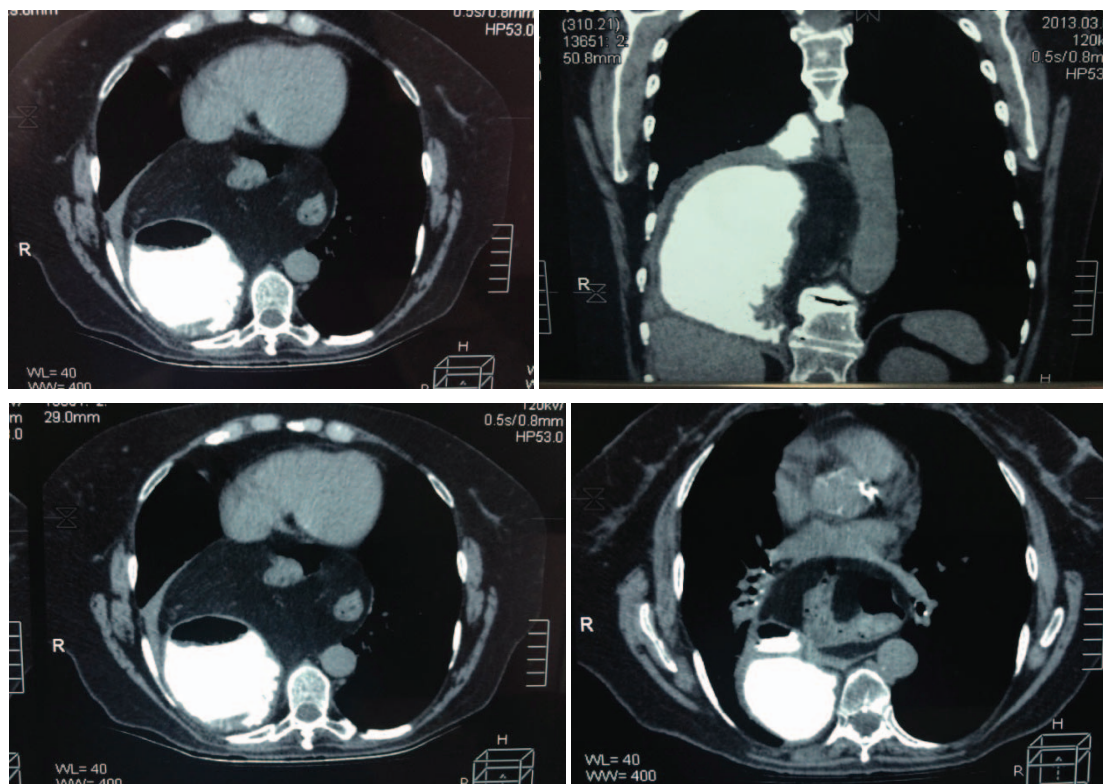


Fig. 2 – Computed tomography (CT) findings are dominated by the large rear right diaphragmatic hernia with the hernia sac that reaches the carina trachea and urges the principal bronchi. The stomach, duodenum and proximal part of jejunal winds, as well as greater amount of omental and mesenteric adipose tissue are localized in hernial sac.

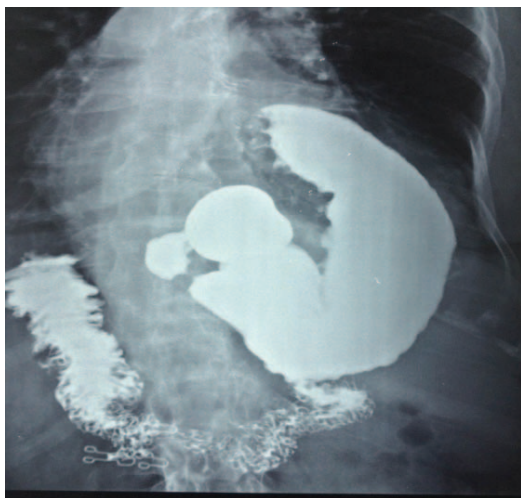


Fig. 3 – Swallowing barium shows on the right side Bochdalek hernia with the major part of the stomach located in the chest.

At first, right side posterolateral thoracotomy was performed through fifth intercostal space. During the operation, exploration showed the right lung with signs of compressive atelectasis with the presence of large diaphragmal hernia localized in posterolateral region. Careful removal of massive adhesions between the right lung and hernial sac was done and then the hernial sac was repositioned into abdominal cavity, after which a defect on diaphragm with di-

mensions approximately 9×6 cm was noted. Subsequently, medial laparotomy was performed and digestive organs which were involved in the described hernia (stomach with duodenum and part of greater omentum as well as proximal part of jejunum) were separated through carefully adhesiolysis, partially blunt, partially sharply, but without any organ injury, since they were largely conjoined. Defect on diaphragm was reconstructed with prolen mesh. Further exploration of the abdominal cavity showed calculi within the gall bladder, due to which retrograde cholecystectomy was done. There were no post-operative complications. The patient was discharged without any respiratory or gastrointestinal difficulties. Chest X-ray examination 15 days after the surgery showed no signs of herniation of abdominal organs into chest cavity.

Discussion

Congenital diaphragmatic hernias, clinically represented in adult life, are extremely rare. They can occur through the frontal parasternal opening (Morgagni) or through the posterolateral opening (Bochdalek). Posterolateral, Bochdalek hernia is the most common type of congenital diaphragmatic hernias (95%)¹. Most Bochdalek hernias are present during neonatal life, have poor prognosis and are often associated with congenital anomalies of the lungs. Overall prevalence of Bochdalek hernias in adults is 6%². Clinical manifestations of Bochdalek hernias in children and

adults are different. In children it is usually presented by breathing disorders and cyanosis⁷, while in adults it can be presented in 2 ways. Patients frequently have vague, mostly gastrointestinal symptoms. The most common gastrointestinal symptoms in adults are: recurrent abdominal pain, flatulence after a meal and vomiting⁸. Chest pain, dyspnea and wheezing, which are the symptoms of the respiratory tract, may occur in adults as well, which was the case with our patient. These symptoms may be followed by attacks or episodes of incarceration, with serious consequences.

These symptoms may be temporary. It is believed that late presentation of symptoms or the absence of symptoms can occur due to occlusion of diaphragmal defect within the abdomen.

The diagnosis of Bochdalek hernia can be made by conventional radiological methods like plain radiographs and barium studies⁷.

Congenital diaphragmatic hernias are uncommon diagnosis among the adults, mostly because they occur in childhood. Unclear and nonspecific clinical presentation results in late diagnosis. They are diagnosed accidentally in adults, as an incidental medical finding or when the symptoms appear. The diagnosis of Bochdalek hernia in adulthood is problematic because of the rarity of this disease and the variety of the presenting symptoms. The presence of bowel sounds within the chest and the absence of breath sounds are typical findings associated with Bochdalek hernia⁹. They can be easily detected by radiography. Ultrasound has an important role in prenatal diagnosis of this condition. Regarding postnatal evaluation of diaphragmatic hernia, ultrasound helps in marking of the whole diaphragm, allowing an estimation of which organs are causing a herniation inside the thoracic cavity. Computed tomography is the most accurate way of diagnosing. In adults in whom the diagnosis is missed, CT has a very important role. Without CT, nearly 38% of adults had a wrong diagnosis – pleural effusion, pleural empyema,

pulmonary cyst and pneumothorax⁷. Clinical presentation of a right-sided Bochdalek hernia can also manifest as strangulation of the contents of the hernia, colon necrosis and hemothorax. Previous data indicate that the final diagnosis is confirmed by CT⁸.

The treatment of Bochdalek hernia is surgical, usually without recidivism and patients are usually without symptoms after the intervention⁷. Traditionally, the surgical management of diaphragmatic defects were performed via laparotomy and/or thoracotomy. Several authors suggested an abdominal approach for left-sided defects and a thoracic approach for right-sided hernias. The improved ability of separating adhesions between the hernial sac and pleura is the main advantage of the transthoracic repair.

In our patient, thoracotomy and adhesiolysis were performed at first, then, the laparotomy with adhesiolysis of largely conjoined organs within the present hernia and closure of diaphragmal defect with polypropylene netting. Regardless to surgical procedure applied, there are controversies on repair of Bochdalek hernia, such as dissection of the hernial sac and the usage of grafts. Regarding the fact that dissection of hernial sac is largely attributed to a high risk of pleural injuries, most surgeons leave hernial sac at its primary position. Smaller defects are easier to repair while the repair of larger ones lead to reduction of volume of intra-abdominal cavity. The choice of procedure depends on the surgeon's experience⁹.

Conclusion

We presented a rare case of right-sided Bochdalek hernia which was discovered at late age and surgically treated with success. Even though it is rare, this disorder should be recognised, examined and treated appropriately to avoid complications.

R E F E R E N C E S

1. *Gedik E, Tuncer MC, Onat S, Avcı A, Taçyıldız I, Bac B.* A review of Morgagni and Bochdalek hernias in adults. *Folia Morphol (Warsz)* 2011; 70(1): 5- 12.
2. *Shah SN, Chengappa D, Irfan , Arun M.* Incidental Congenital Diaphragmatic Hernia (Bochdalek) in an Asymptomatic Adult: A Case Report and Review of Literature. *IOSR J Dent Med Sci* 2015; 14(3): 104- 9.
3. *Saeed U, Mazhar N, Zameer S.* Large Hiatal Hernia in Infancy with Right Intrathoracic Stomach Along with Left Sided Morgagni Hernia. *J Coll Physicians Surg Pak* 2014; 24 Suppl 3: S178- 9.
4. *Garófano-Jerez JM, de Dios López-González J, Valero-González AM, Valenzuela-Barranco M.* Posterolateral Bochdalek diaphragmatic hernia in adults. *Rev Esp Enferm Dig* 2011; 9(103): 484- 91.
5. *Hamid KS, Rai SS, Rodríguez JA.* Symptomatic Bochdalek hernia in an adult. *JLS* 2010; 14(2): 279- 81.
6. *Rajput MZ, Fisichella PM.* An 81-year-old gentleman with symptomatic Bochdalek hernia. *World J Gastrointest Surg* 2013; 5(7): 222- 3.
7. *Alam A, Chander BN.* Adult Bochdalek Hernia. *Med J Armed Forces India* 2005; 61(3): 284- 6.
8. *Laaksonen E, Silvasti S, Hakala T.* Right-sided Bochdalek hernia in an adult: a case report. *J Med Case Rep* 2009; 3: 9291.
9. *Sutedja B, Muliati Y.* Laparoscopic repair of a Bochdalek hernia in an adult woman. *Asian J Endosc Surg* 2015; 8(3): 354-6.

Received on February 1, 2016.
Revised on November 2, 2016.
Accepted on November 3, 2016.
Online First December, 2016.